

Veterinary Specialists of Alaska, P.C. Client Information Sheet: Cranial Cruciate Ligament Rupture

Cranial Cruciate Ligament Rupture

Nelson Priddy II., DVM, DACVS; Mike Edwards, DVM, MS, DACVS; Dirsko J.F. von Pfeil, Dr.med.vet., DVM, DACVS, DECVS

The cranial cruciate ligament (CCL) is one of the main stabilizing structures in the canine or feline stifle (knee) joint. Its role is to help maintain a normal relationship between the femur (thigh bone) and tibia (shin bone) in all angles of motion. More specifically, the CCL prevents the tibia from sliding forward, relative to the femur. The cranial cruciate ligament also prevents excessive internal rotation of the tibia and plays a role in limiting hyperextension of the stifle (Figure 1).

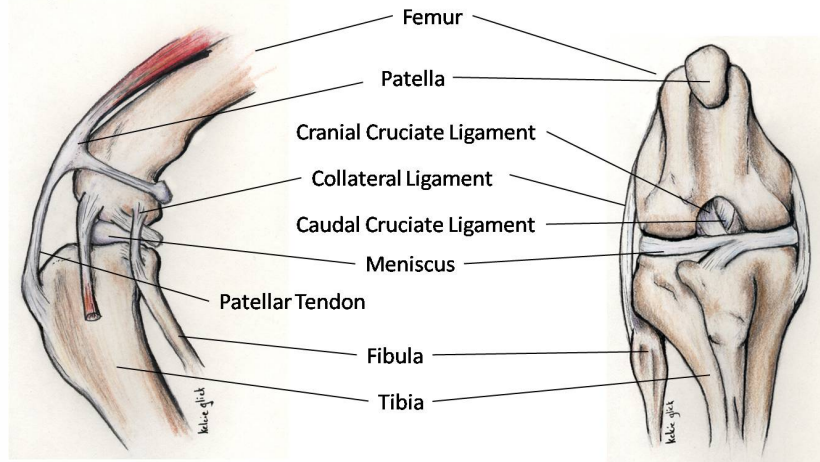


Figure 1: Normal anatomy of the stifle. Left: Side view. Right: Frontal view. The cranial cruciate ligament keeps the stifle stable.

When the CCL ruptures or tears, the stifle becomes unstable and the normal relationship between the femur and tibia is altered leading to inflammation (arthritis) and pain. If the instability is not treated, lameness frequently persists and arthritis will progress. Because of the instability in the stifle caused by the ruptured cranial cruciate ligament, the medial meniscus can be pinched between the femur and the tibia causing irreparable damage. Subjectively, it appears that patients with CCL ruptures and meniscal damage are more painful (i.e. more lame) than patients without meniscal damage (Figure 2).

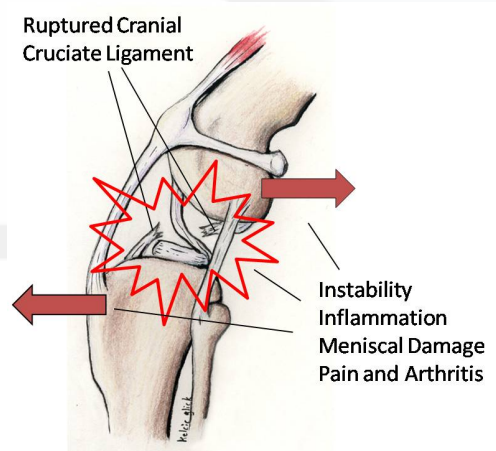


Figure 2: Instability of the stifle after cranial cruciate ligament rupture leads to inflammation, meniscal damage, pain and arthritis

Veterinary Specialists of Alaska, P.C. Client Information Sheet: Cranial Cruciate Ligament Rupture

Incidence:

CCL rupture occurs much more frequently in dogs than in cats. It is the most common orthopedic injury of the hind limb in dogs in this practice and is the most common cause of degenerative joint disease in the stifle joint. CCL rupture occurs in dogs of all sizes but is more prevalent in large and giant breeds. Large-breed dogs are more severely affected by the resulting instability. Typically, it is a condition seen in middle-aged dogs, although it can be seen at any age.

Cause and Clinical Signs:

There is no single cause of CCL rupture. In most canine patients, there is a chronic deterioration of the cranial cruciate ligament that eventually leads to complete rupture and possible meniscal damage. This would suggest a conformational or possibly immune-mediated issue. In the remaining patients, the tear is truly traumatic resulting from sudden, severe twisting or hyperextension of the stifle. The lameness often begins as a slight stiffness in the affected limb most notable after heavy exercise. The lameness typically progresses to the extent that the dog will refuse to use the affected limb. It is not uncommon for the cranial cruciate ligaments to deteriorate in both hind limbs simultaneously. Such patients compensate for this by shifting weight to their forelimbs. They assume a crouched stance and many people notice that their dogs are reluctant to climb stairs or jump into cars. The most common sign of CCL rupture is lameness in the affected hind limb. Any degree of lameness can be appreciated with this disorder depending on the completeness of the tear and the condition of the medial meniscus.

Diagnosis:

The diagnosis is usually made on physical examination. The stifle is manipulated to detect evidence of pain, swelling or instability. Anesthesia may be necessary to move the limb to the extent needed to make the diagnosis because pain from a ruptured CCL can be severe and muscle tension can restrict the motion of the joint.

Radiographs (x-rays) are generally very helpful in making this diagnosis as they can demonstrate effusion (excessive fluid) in the joint as well as osteophytes (bone spurs) which both develop secondary to the arthritis. The ruptured ligament itself will not show up on radiographs. While the presence of effusion and bone spurs are not specific for CCL rupture, they are most commonly associated with CCL rupture and can support the physical examination findings.

Arthroscopic evaluation of the stifle can also be performed to assess the joint in a minimally invasive manner. This allows a magnified view of the interior of the joint. Additionally, it is possible to remove the damaged cruciate ligament and assess the integrity of the medial meniscus.

Treatment:

The goals of therapy are to relieve pain, restore function and minimize the rate of progression and ultimate extent of osteoarthritis by stabilizing the joint. Most patients are able to resume their pre-operative life style. However, many patients develop evidence of arthritis. The best results are obtained when surgery is performed to stabilize the joint and medical therapy is used to alleviate the signs associated with arthritis. Physical rehabilitation is beneficial in regaining muscle mass, muscle strength, and range of motion. There are numerous surgical techniques for the management of CCL rupture in our canine and feline patients. The most common techniques employed at Veterinary Specialists of Alaska, P.C. are tibial plateau leveling osteotomy (TPLO), lateral fabello-tibial suture (LFTS) and the Arthrex TightRope® system. Each technique is described in detail on this web site. Each technique has its advantages and disadvantages. Your board-certified surgeon will explain these options and will work with you to determine the best treatment for your pet.